

Postoperative Impact of Intraoperative Biochemical Changes at the Completion of Parenchymal Division in Living-Donor Liver Transplantation

Ashok Jain,¹ Mark Orloff,¹ Peter Abt,¹ Randeep Kashyap,¹ Parvez Mantry,² Adel Bozorgzadeh¹

Objectives: Biochemical abnormalities after living-donor hepatectomy are attributed to the loss of liver volume and steatosis or fibrosis. In this study, we evaluated the intraoperative biochemical changes caused by the separation of the hepatic lobes before removal and the impact of those changes on postoperative biochemical abnormalities in patients who underwent adult-to-adult living-donor liver transplantation (LDLT).

Materials and Methods: The extent and postoperative impact of the biochemical changes that occur during hepatic parenchymal transection in adult-to-adult LDLT were studied in 38 patients who underwent that procedure (14 men and 24 women; mean age, 39.6 years; age range, 19.5-58.9 years). Preoperative, intraoperative, and postoperative biochemical values for the first 8 postoperative days were compared.

Results: The mean total hepatic volume was 1703.0 mL, the mean weight of the resected mass was 887.0 g (52.6%), and the mean weight of the residual mass was 816.0 g (47.4%). The mean total bilirubin, aspartate amino transferase (AST), and amino alanine transferase (ALT) values were 8.6 U/L, 21.4 U/L, and 27.6 U/L, respectively, before surgery, compared with 27.4 U/L (an increase of 3.2 times), 257.9.2 U/L (an increase of 12.0 times), and 224.64 U/L (an increase of 8.1 times), respectively, after separation of the hepatic lobes.

Patients (n = 21) with an intraoperative ALT value of ≥ 200 had a significantly higher peak postoperative ALT ($P = .001$) than did those (n = 17) with an ALT value of < 200 .

Conclusions: A significant increase in hepatic biochemical parameters occurs at the completion of hepatic parenchymal transection and before the removal of the right hepatic lobe from the donor. This has an impact on postoperative peak enzyme levels in the donor.

Key words: *Living-donor, Intraoperative, Liver injury*

The indications and demand for liver transplantation have increased over the last decade owing to improved outcomes. However, the deceased-donor pool has remained relatively stable. To overcome the demand for this life-saving procedure, increasing numbers of living-donor partial hepatic allografts are being used for transplantation [1-4]. The safety of the living liver donor, during and after the surgical procedure, is of paramount importance because the procedure is performed on a healthy individual who does not otherwise require an operation. Also, the size and quality of the donor liver are important for both donor and recipient outcomes. Donors who are overweight may have fatty infiltrates in their liver, and older donors may have a degree of hepatic fibrosis. A routine percutaneous liver biopsy is performed on all potential donors at our center and at many other centers. Potential donors with significant findings in the results of their liver biopsy may not be considered suitable candidates for partial liver donation [5-9].

Despite careful selection, hepatic dysfunction in the donor after the loss of hepatic mass often occurs [10] and is usually attributed to that loss [8, 11, 12]. However, the biochemical changes indicative of hepatic dysfunction are thought to occur before the

¹Department of Surgery, Division of Transplantation, ²Department of Gastroenterology and Hepatology, University of Rochester Medical Center, Rochester, New York

Acknowledgement: We thank Dr. Manoj Purohit for help in finalizing this manuscript.

Address reprint requests to: Ashokumar Jain, University of Rochester Medical Center, Department of Surgery, Division of Transplantation, Box SURG, 601 Elmwood Avenue, Rochester, NY 14642 USA

Phone: 00 585 275 58 75 **Fax:** 00 585 271 79 29 **E-mail:** ashok_jain@urmc.rochester.edu

Presented in part at The International Liver Transplant Society Meeting, July 20-24, 2005, Los Angeles, California.

Experimental and Clinical Transplantation (2006) 2: 544-548

loss of hepatic mass and purely as a result of the division of the hepatic lobes. To our knowledge, that degree of damage and its impact on overall postoperative hepatic biochemical abnormalities have never been studied. In this study, we examined 2 factors: the intraoperative biochemical changes caused by the separation of the hepatic lobes before removal and the impact of those changes on postoperative biochemical abnormalities in patients who underwent adult-to-adult living-donor liver transplantation (LDLT).

Materials and Methods

Thirty-eight LDLT donors (14 men and 24 women; mean age, 39.6 ± 9.9 years) were examined for intraoperative biochemical changes caused by the separation of the hepatic lobes. The mean total hepatic volume was 1703.0 ± 363.3 mL, as calculated by the volumetric mapping of abdominal computer tomographic (CT) scans [13-15]. The same surgical team performed all donor operations. The hepatic lobes were separated after the right hepatic vein, right hepatic artery, and right portal vein had been identified and dissected. Intraoperative cholangiography was performed through the cystic duct. The division line was determined by the transient obliteration of inflow from the right-sided hepatic arterial and right-sided portal venous flow.

All hepatic resections were performed with a Cavitronic Ultrasound Surgical Aspirator (CUSA) (Valleylab Inc, Boulder, Colo), unipolar electrocautery, Liga clips, Prolene sutures, and silk ties and the use of a low central venous pressure (1-5 cm of water) but without the Pringle maneuver. All donors had undergone liver function tests before surgery and after separation of the hepatic lobes. Biochemical changes were measured daily before discharge. Intraoperative biochemical changes were compared with preoperative values, postoperative values, and the remaining hepatic mass (estimated by CT volumetric analysis minus the weight of the hepatic mass removed) in relation to body weight.

All values are presented as the mean \pm standard deviation. The mean intraoperative values and postoperative values were compared with the results of a *t* test. A *P* value of less than .05 was considered significant. SPSS software (Statistical Package for the Social Sciences, version 13.0, SSPS Inc, Chicago, Ill, USA) was used for all statistical analyses.

Results

All donors experienced a smooth operative procedure. The estimated average blood loss was < 300 mL, and none of the patients required a blood transfusion or a return to the operative room for the treatment of complications. The mean weight of liver mass removed was 887.0 ± 200.4 g (52.6%), and the mean weight of residual liver mass was 816.0 ± 247.2 g (47.4%). The mean remnant hepatic mass-weight ratio was $1.0\% \pm 0.3\%$.

Intraoperative biochemical changes

All donors demonstrated changes in their biochemical parameters to varying extents. The mean total bilirubin value before surgery was 8.6 ± 3.4 $\mu\text{mol/L}$, which increased to 27.4 ± 12.0 $\mu\text{mol/L}$ (an increase of 3.2 times) after separation of the hepatic lobes and had normalized by postoperative day 8. The mean preoperative aspartate amino transferase (AST) value was 21.4 ± 5.1 U/L, which increased to 257.9 ± 90.2 U/L (an increase of 12.0 times) after separation of the lobes. The mean preoperative amino alanine transferase (ALT) value was 27.6 ± 11.0 U/L, which increased to 224.6 ± 90.4 U/L (an increase of 8.1 times) after separation of the lobes (Figure A, B, C).

Impact of intraoperative biochemical changes on postoperative parameters in donors

To examine the impact of an increase in intraoperative biochemical parameters on postoperative changes, the donors were grouped into categories based on their intraoperative bilirubin, AST, and ALT values and residual hepatic mass. These changes were correlated with peak postoperative values as shown in the Table. There were no differences in peak postoperative values between donors who had an intraoperative total bilirubin value of < 25.7 $\mu\text{mol/L}$ and those with a value of ≥ 25.7 $\mu\text{mol/L}$, or between those who had more than a 3-fold rise or less in the bilirubin value. Similarly, when donors who had an AST level of < 200 U/L were compared with those who had an AST level of ≥ 200 U/L, no significant effect was found on the postoperative peak AST value ($P = .188$). However, donors with an intraoperative ALT level of ≥ 200 had a significantly higher postoperative peak ALT level than did those with an intraoperative ALT level of < 200 U/L (mean, 232.2 ± 79.0 U/L vs 385.9 ± 132.0 U/L, respectively; $P = .001$) (Table).

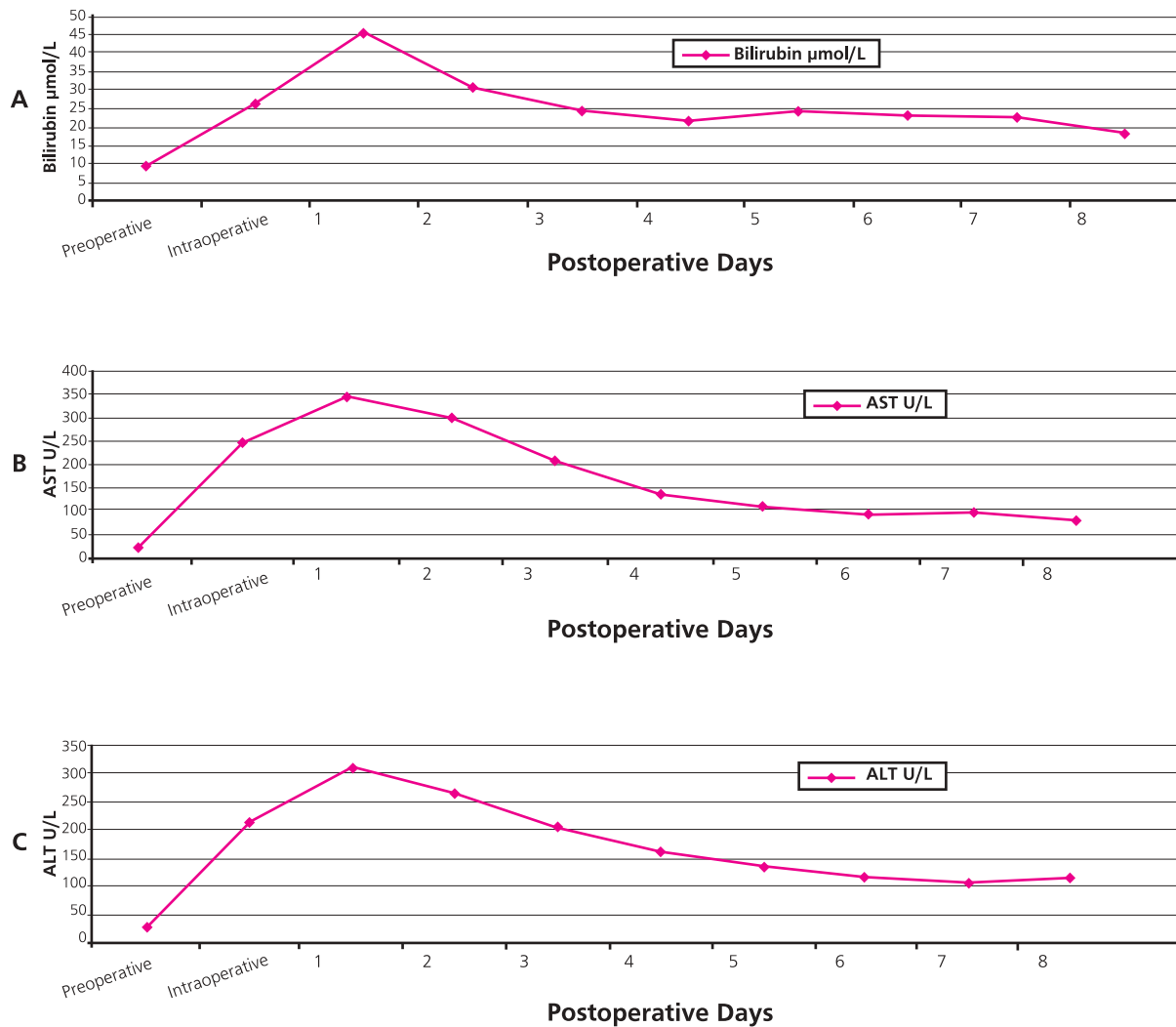


Figure A, B, and C. (A) Total bilirubin $\mu\text{mol/L}$, (B) AST U/L, and (C) ALT U/L values preoperatively, intraoperatively, and during the first 8 postoperative days. AST, Aspartate amino transferase; ALT, amino alanine transferase.

Impact of residual hepatic mass and hepatic mass donor-weight ratio

The mean total bilirubin, AST, and ALT values were higher in patients ($n = 17$) with a residual hepatic mass of < 750 g than in those ($n = 21$) with a residual mass of ≥ 750 g. However, that difference was not significant. When the residual hepatic mass was $< 1\%$ of the patient's body weight ($n = 18$), the mean total bilirubin, AST, and ALT values were higher than those in the patients ($n = 20$) with a residual hepatic mass of $\geq 1\%$, although that difference also did not reach statistical significance (Table).

Impact of intraoperative biochemical changes on postoperative parameters in recipients

Similar changes in the biochemical profiles of the recipients were examined with respect to intraopera-

tive changes in the donors. Unfortunately, the pretransplant biochemical profiles of the recipients varied greatly; hence, no meaningful comparison could be made.

Discussion

Knowledge of the surgical anatomy of the hepatic lobes, its segments, and the segmental nature of the portal venous supply makes the division of the hepatic segments and lobes possible without major crossing between the segments [16-18].

Hepatic resection has been performed successfully over last 3 decades in patients with a primary hepatic malignancy, metastatic disease, or a symptomatic benign lesion [16]. Various modifications have been made in techniques for hepatic lobe resection to

Table 1. Postoperative peak biochemical changes in relation to intraoperative biochemical changes, residual hepatic mass, and residual liver-mass to donor-weight ratio

Impact of intraoperative biochemical parameters				
Biochemical Parameters	Intraoperative Value	n	Mean Postoperative Peak Value	P Value
Total bilirubin ($\mu\text{mol/L}$)	< 25.7	18	42.7 \pm 22.2	.533
	\geq 25.7	20	47.9 \pm 18.7	
Rise in bilirubin (times)	< 3	18	49.6 \pm 22.2	.350
	\geq 3	20	42.7 \pm 17.1	
AST (U/L)	< 200	9	287.0 \pm 74.8	.188
	\geq 200	29	373.4 \pm 187.1	
ALT (U/L)	< 200	17	232.2 \pm 79.0	.0001
	\geq 200	21	385.9 \pm 132.0	
Impact of residual hepatic mass (g)				
Biochemical Parameters	Hepatic Mass	n	Mean Postoperative Peak Value	P Value
Total bilirubin ($\mu\text{mol/L}$)	< 750	17	42.7 \pm 18.7	.475
	\geq 750	21	53.0 \pm 24.2	
AST (U/L)	< 750	17	330.1 \pm 67.4	.466
	\geq 750	21	371.4 \pm 222.2	
ALT (U/L)	< 750	17	286.4 \pm 106.7	.210
	\geq 750	21	342.0 \pm 151.5	
Impact of residual volume donor weight ratio (%)*				
Biochemical Parameters	Ratio (%)	n	Mean Postoperative Peak Value	P Value
Total bilirubin ($\mu\text{mol/L}$)	< 1.0	18	54.7 \pm 20.5	.127
	\geq 1.0	20	37.6 \pm 17.1	
AST (U/L)	< 1.0	18	385.0 \pm 226.9	.335
	\geq 1.0	20	324.1 \pm 93.4	
ALT (U/L)	< 1.0	18	334.9 \pm 172.4	.431
	\geq 1.0	20	301.1 \pm 90.0	

AST, Aspartate amino transferase; ALT, amino alanine transferase.

*Residual volume donor weight ratio (%) = [Total volume on computed tomographic volumetry (L) - weight of graft (kg)]/weight of patient (kg) x100

reduce blood loss and operative time. The intraoperative use of ultrasonography to identify hepatic veins and portal structures enables surgeons to define the plane of dissection. Electrocautery (both unipolar and bipolar) and ultrasonic harmonic scalpels are useful in controlling the bleeding from small vessels. The use of a CUSA and a water jet increases the safety of hepatic resection [19-22].

The shortage of deceased-donor liver allografts and an increasing demand for LDLT has led to an increase in the number of living-donor hepatic resections that are performed. Strict guidelines, which are in place to ensure donor safety, include the performance of liver resection by skilled surgical teams experienced in hepatobiliary surgery and liver transplantation in addition to an institutional infrastructure

that ensures the adequate postoperative care of donors [23-30]. At present, however, standardized information on postoperative donor morbidity is lacking [31].

There is a constant need to develop new strategies, plans, and techniques to improve the safety of liver donors. The unique ability of remnant liver to regenerate allows postoperative biochemical hepatic abnormalities to correct with time. Biochemical hepatic dysfunction after resection is usually attributed to a loss of hepatic mass. A lower residual liver mass may require a longer time to regenerate and may be the cause of a greater postoperative increase in the levels of total bilirubin and hepatic enzymes [32, 33]. We observed (as did other investigators) a correlation between the residual mass, the body-weight ratio, and the degree of postresection hepatic dysfunction. We found that the actual residual mass per se did not affect the degree of hepatic dysfunction.

Schemmer and colleagues reported that gentle in situ manipulation with the destruction of Kupffer cells produced a significant effect on hepatic injury in a rat model [34]. AST and ALT are hepatic cytoplasmic enzymes. During parenchymal handling and division, cell wall damage leads to the release of those enzymes in circulation and a subsequent elevation in the levels of hepatic enzymes. Removal of the transected hepatic mass further increases liver enzyme levels. However, the extent of that increase in liver enzymes has not been reported in human hepatic resection. The intraoperative increase in the bilirubin level that resulted from hepatic parenchymal division was a somewhat surprising and novel finding of this study.

We have shown that the postoperative biochemical abnormalities that occur after the resection of a hepatic lobe in patients who have undergone LDLT develop intraoperatively during the hepatic parenchymal division and that there is a further increase in those abnormalities during the first few days after the removal of the hepatic lobe. A mean increase in the levels of bilirubin of up to 3.2 times, ALT of up to 8.1 times, and AST of up to 12.0 times greater than preoperative values has been observed during the hepatic parenchymal division. In addition, we found that the ALT value after hepatic parenchymal division correlates with the peak postoperative ALT value, independent of the residual hepatic mass or the residual mass donor-weight ratio in the donors. Further investigation is necessary to determine whether factors such as tissue injury and inflamma-

tion along the margin of the parenchymal division or simply the handling and manipulation of hepatic tissue during that division are responsible for this finding.

References

1. UNOS. UNet: Organ Procurement and Transplantation Network. Available at: <http://www.unos.org>. Accessed July 18, 2006.
2. Testa G, Malago M, Broelsch CE. Living-donor liver transplantation in adults. *Langenbecks Arch Surg* 1999; 384: 536-543
3. Trotter JF, Wachs M, Everson GT, Kam I. Adult-to-adult transplantation of the right hepatic lobe from a living donor. *N Engl J Med* 2002; 346: 1074-1082
4. Settmacher U, Theruvath T, Pascher A, Neuhaus P. Living-donor liver transplantation—European experiences. *Nephrol Dial Transplant* 2004; 19: iv16-iv21
5. Ratziu V, Giral P, Charlotte F, Bruckert E, Thibault V, Theodorou I, et al. Liver fibrosis in overweight patients. *Gastroenterology* 2000; 118: 1117-1123
6. Rinella ME, Alonso E, Rao S, Whittington P, Fryer J, Abecassis M, et al. Body mass index as a predictor of hepatic steatosis in living liver donors. *Liver Transpl* 2001; 7: 409-414
7. Ryan CK, Johnson LA, Germin BI, Marcos A. One hundred consecutive hepatic biopsies in the workup of living donors for right lobe liver transplantation. *Liver Transpl* 2002; 8: 1114-1122
8. Pomfret EA, Pomposelli JJ, Lewis WD, Gordon FD, Burns DL, Lally A, et al. Live donor adult liver transplantation using right lobe grafts: donor evaluation and surgical outcome. *Arch Surg* 2001; 136: 425-433
9. Monsour HP Jr, Wood RP, Ozaki C, Katz S, Clark J, Dyer C, et al. Utility of preoperative liver biopsy in live-related donor patients for liver transplantation. *Transplant Proc* 1994; 26: 138-139
10. Kim DG, Na SE, Chung ES, Moon IS, Lee MD, Kim IC. Donor safety in living donor liver transplantation using the right lobe. *Transplant Proc* 2003; 35: 53-54
11. Pomfret EA. Early and late complications in the right-lobe adult living donor. *Liver Transpl* 2003; 9: S45-S49
12. Pomfret EA, Pomposelli JJ, Gordon FD, Erbay N, Lyn Price L, Lewis WD, et al. Liver regeneration and surgical outcome in donors of right-lobe liver grafts. *Transplantation* 2003; 76: 5-10
13. Frericks BB, Caldarone FC, Nashan B, Savellano DH, Stamm G, Kirchoff TD, et al. 3D CT modeling of hepatic vessel architecture and volume calculation in living donated liver transplantation. *Eur Radiol* 2004; 14: 326-333
14. Harms J, Bartels M, Bourquain H, Peitgen HO, Schulz T, Kahn T, et al. Computerized CT-based 3D visualization technique in living related liver transplantation. *Transplant Proc* 2005; 37: 1059-1062
15. Higashiyama H, Yamaguchi T, Mori K, Nakano Y, Yokoyama T, Takeuchi T, et al. Graft size assessment by preoperative computed tomography in living related partial liver transplantation. *Br J Surg* 1993; 80: 489-492
16. Blumgart LH. Surgery of the liver and biliary tract. In: Blumgart LH, Fong Y, eds. *Surgery of the liver and biliary tract*. 3rd ed. Vol II. London, W.B. Saunders Company Ltd; 2000, p 1679-1713
17. Lafortune M, Madore F, Patriquin H, Breton G. Segmental anatomy of the liver: a sonographic approach to the Couinaud nomenclature. *Radiology* 1991; 181: 443-448
18. Emond JC, Renz JF. Surgical anatomy of the liver and its application to hepatobiliary surgery and transplantation. *Semin Liver Dis* 1994; 14: 158-168
19. Hata Y, Sasaki F, Takahashi H, Ohkawa Y, Taguchi K, Une Y, et al. Liver resection in children, using a water-jet. *J Pediatr Surg* 1994; 29: 648-650
20. Une Y, Uchino J, Horie T, Sato Y, Ogasawara K, Kakita A, et al. Liver resection using a water jet. *Cancer Chemother Pharmacol* 1989; 23: S74-S77
21. Fasulo F, Giori A, Fissi S, Bozzetti F, Doci R, Gennari L. Cavitron Ultrasonic Surgical Aspirator (CUSA) in liver resection. *Int Surg* 1992; 77: 64-66
22. Little JM, Hollands MJ. Impact of the CUSA and operative ultrasound on hepatic resection. *HPB Surg* 1991; 3: 271-277; discussion 277-278
23. Clavien PA. Third Forum on Liver Transplantation Living donor liver transplantation. Who needs it? How to do it? Who should do it? *J Hepatol* 2005; 43: 11-12
24. Surman OS. The ethics of partial-liver donation. *N Engl J Med* 2002; 346: 1038
25. Fan ST, Lo CM, Liu CL, Yong BH, Chan JK, Ng IO. Safety of donors in live donor liver transplantation using right lobe grafts. *Arch Surg* 2000; 135: 336-340
26. Malago M, Testa G, Marcos A, Fung JJ, Siegler M, Cronin DC, et al. Ethical considerations and rationale of adult-to-adult living donor liver transplantation. *Liver Transpl* 2001; 7: 921-927
27. Shiffman ML, Brown RS Jr, Olthoff KM, Everson G, Miller C, Siegler M, et al. Living donor liver transplantation: summary of a conference at The National Institutes of Health. *Liver Transpl* 2002; 8: 174-188
28. US Department of Health and Human Services Advisory Committee on Organ Transplantation. Recommendations to the secretary. Available at: <http://www.organdonor.gov/acotrecs.html>. Accessed July 18, 2006.
29. New York State Committee on Quality Improvement in Living Liver Donation. A report to: New York State Transplant Council and New York State Department of Health. Available at: http://www.health.state.ny.us/nysdoh/liver_donation/pdf/liver_donor_report_web.pdf. Accessed July 18, 2006.
30. Eghtesad B, Jain AB, Fung JJ. Living donor liver transplantation: ethics and safety. *Transplant Proc* 2003; 35: 51-52
31. Beavers KL, Sandler RS, Shrestha R. Donor morbidity associated with right lobectomy for living donor liver transplantation to adult recipients: a systematic review. *Liver Transpl* 2002; 8: 110-117
32. Shirabe K, Shimada M, Gion T, Hasegawa H, Takenaka K, Utsunomiya T, et al. Postoperative liver failure after major hepatic resection for hepatocellular carcinoma in the modern era with special reference to remnant liver volume. *J Am Coll Surg* 1999; 188: 304-309
33. Heaton N. Small-for-size liver syndrome after auxiliary and split liver transplantation: donor selection. *Liver Transpl* 2003; 9: S26-S28
34. Schemmer P, Schoonhoven R, Swenberg JA, Bunzendahl H, Thurman RG. Gentle in situ liver manipulation during organ harvest decreases survival after rat liver transplantation: role of Kupffer cells. *Transplantation* 1998; 65: 1015-1020