

Chylous Ascites After Liver Transplant: Case Report and Review of Literature

Amar Nath Mukerji, Esther Tseng, Andreas Karachristos, Manoj Maloo, Ashokkumar Jain

Abstract

Case: A 62-year-old man with cirrhosis, hepatitis C, and hepatocellular carcinoma, underwent a liver transplant. On day 11 after surgery, a chylous leak from a partial wound dehiscence was noted. The leak did not respond to 2 weeks of uninterrupted, fat-free clear liquid diet and 12-hour total parenteral nutrition at night. The same treatment was continued for another 6 weeks with fatty meal challenge every weekend, which he failed. He was then given a fat-free clear liquid diet, 24-hour total parenteral nutrition, and octreotide 100 µg subcutaneously every 8 hours for 14 days. A prompt response was noted. His recovery was excellent at the time of this writing (9 months' follow-up).

Discussion: Eleven major cases have been reported with 9 cases being managed conservatively. Four were given a diet plus total parenteral nutrition without octreotide producing a cure in 3 to 36 days. Two cases (including ours) were given the diet and total parenteral nutrition, which failed; octreotide was then added, and these cases were cured in 2 to 4 weeks. Therefore, diet with total parenteral nutrition failed in 33.3% of the cases (2/6). In 3 cases, octreotide was used from the outset. They were all cured in ≤ 2 weeks. One case was operated on for peritonitis; chylous ascites was found and a leak was ligated. One patient with congenital lymphatic disorder underwent peritoneovenous shunting. Octreotide was not used in any of the cases of chylous ascites that were treated surgically.

Conclusions: If exploratory surgery is done for any other reason, it is best to identify a chylous leak and ligate it. Otherwise, we recommend octreotide combined with a fat-free, clear liquid diet, and supplementation with medium chain triglycerides and total parenteral nutrition from the outset.

Key words: *Chylous ascites, Liver transplant*

Introduction

Orthotopic liver transplant (OLT) is associated with several postoperative complications. Chylous ascites after OLT is rare. We discuss our experience with one such case and review the literature.

Case Report

A 62-year-old white man presented with cirrhosis owing to chronic hepatitis C with hepatocellular carcinoma. He underwent transarterial chemoembolization with Adriamycin, cisplatin and mitomycin C, twice, 7 and 2 months before the transplant. The last preoperative computed tomography (CT) scan showed a 2.6 × 2.1 cm treated lesion in segment VIII of the liver.

He received a deceased-donor whole liver transplant. The portal vein was thought to be occluded partially by a thrombus in an earlier contrast-enhanced CT scan, but during surgery, it was found to be completely occluded. Brisk portal flow was obtained after extraction of a pale thrombus. The new organ was placed piggy-back on the inferior vena cava, and the portal veins and common bile ducts were anastomosed end-to-end. The recipient's hepatic artery was dissected beyond the origin of the gastroduodenal artery, and an end-to-end anastomosis was made with the donor's celiac axis using a Carrel patch. The donor's left

From Temple University Hospital, Philadelphia, PA, USA

Acknowledgements: No funding or grant support was received from any agency. The authors have no conflicts of interest to declare.

Corresponding author: Ashokkumar Jain, MD, FACS, Suite 640, Parkinson Pavilion, Temple University Hospital, 3401 North Broad Street, Philadelphia, PA 19140 USA
Phone: +1 215 707 8538 Fax: +1 215 707 5960 E-mail: Ashokkumar.Jain@tuhs.temple.edu

Experimental and Clinical Transplantation (2013) 4: 367-374

gastric, splenic, and gastroduodenal arteries were ligated. The surgery was uneventful.

About 500 mL of turbid fluid was noted in the abdomen at the start of surgery. It was reported as bacteriologically sterile subsequently. Pathologically, no viable tumor was identifiable in the explanted liver or in the portal vein clot.

The immediate postoperative recovery was uneventful. The patient was extubated within 24 hours, and ambulatory in 48 hours. Regular feeds were started on fourth postoperative day, with progressive advancement of the diet, which was well tolerated. Liver function test results normalized rapidly within a week after the transplant, and the patient was discharged home on the eighth day in satisfactory condition, with total bilirubin levels of 13.7 $\mu\text{mol/L}$, aspartate aminotransferase 0.68 $\mu\text{kat/L}$, and alanine aminotransferase 2.5 $\mu\text{kat/L}$.

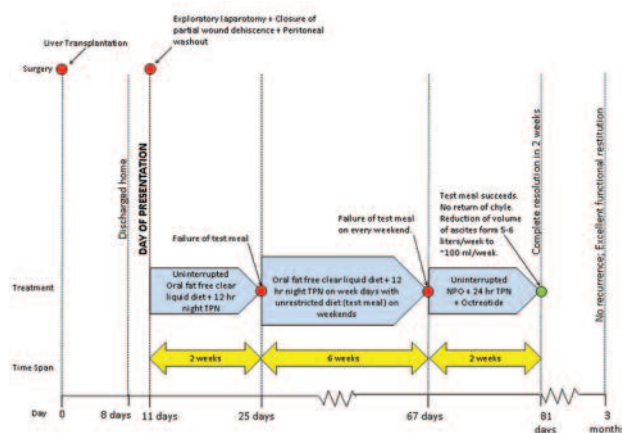
On postoperative day 11, the patient was readmitted with a 1-cm region in the left portion of the Chevron incision leaking chylous fluid. He was taken back to the operating suite where the abdomen was washed out, and the fascial edge was freshened and closed again. During surgery, he was given methylene blue diluted with whole milk through a nasogastric tube. No specific point of leakage of chyle was located intraoperatively. A single subhepatic drain was inserted. The ascitic fluid cell count was 410/ mm^3 with 84% lymphocytes and ascitic fluid triglyceride was 4.78 mmol/L. The Gram stain was negative, and he was diagnosed as having chylous ascites.

Following surgery, he was given a fat-free clear diet and 12-hour total parenteral nutrition (TPN) at night that was continued without a break for 14 days. The chyle cleared immediately when we eliminated dietary fat. However, there would be rapid reaccumulation of clear ascites leading to uncomfortable distension and sometimes a leakage around the drain site necessitating drainage twice per week. About 5 to 6 liters of ascitic fluid was drained each week. After 14 days, a fatty test meal failed, with the fluid turning chylous again.

The patient was discharged home with the drain clipped. At home, he took a fat-free clear diet orally during the day and 12 hours of TPN at night. He was allowed an unrestricted diet over the weekends to assess treatment response. The patient returned to the clinic twice a week. Abdominal distension was noted on every visit. About 2 to 3 liters of fluid was

drained each time. When no response was noted after 6 weeks, the patient was readmitted. Oral nutrition were stopped, and only fat-free clear liquids were allowed with 24-hour TPN. Octreotide 100 μg was administered subcutaneously every 8 hours. The chyle cleared, and there was considerable reduction in the volume of ascites, to < 100 mL/d. After 14 days of treatment, a regular meal was allowed, and the chyle did not return. No abdominal distension was noted after another week on a regular diet. The drain was removed after a last confirmatory drainage that showed a fluid triglyceride level of 0.38 mmol/L. After more than three months' follow-up since the cessation of chylous ascites, the patient had excellent recovery and high degree of functional restitution. His hospital course is summarized in Figure 1.

Figure 1. Timeline of Treatment Course



Discussion

Incidence

Chylous ascites is rare, reported at between 1 in 20 000 to 1 in 187 000 hospital admissions.^{1,2} Postoperative chylous ascites is of specific interest in this discussion. Kaas and associates³ reported a 1.1% incidence after oncologic abdominal resections. However, when the population was restricted to high-risk cases (defined as cases with tumor resections in upper abdomen or retroperitoneum, with or without lymph node dissection), the incidence was 7.4%.³

The literature suggests that after OLT, chylous ascites is a rare occurrence. A literature search yielded 11 major case reports including ours (summarized in Table 1). We found 2 more studies briefly mentioning post-OLT chylous ascites.

Table 1. Compilation of Major Case Reports for Chylous Ascites After Liver Transplant

Author and Year	Age and Sex	Diagnosis	Donor	Presentation	Treatment				Days for Cure	Hospital Course
					Day of Δ.	NPO + TPN	Octreotide	Surgery		
Conservative Treatment Without Using Octreotide										
Asfar, 1994	59, M	α-1-AT Def	D	Chyle in drains	4	N	N	N	36	15 d × (FF + ETF + MCT) → Recurrence on resuming diet → 6 d × (FF + ETF + MCT) → Recurrence on fatty test meal → 15 d × (Clr + ETF + MCT) → Final resolution
Gaglio, 1996	49, M	Cryptogenic	D	Chylous leak from incision and drains	3	Y	N	N	3-4	Graft failure after 1st OLT, 2nd OLT in 48 h with iliac a. graft from infrarenal aorta for poor hepatic flow; presented with chylous leak from incision and drains, cleared in 3-4 days with TPN.
Senyuz, 2001	36, M	Hep B	D	Chylous leak in drains	12	Y	N	N	12	12 d × (NPO + TPN) → Final resolution.
Koluglu, 2008	11, M	FHF of unknown cause in YNS	L	Chylous leak in drains	17	N	N		6	Surgically explored for biliary peritonitis presenting 11 d after OLT. 17 d after OLT chylous leak found in drains → treated with LF + MCT + high protein → resolved → in 6 d.
Conservative Treatment Using Octreotide Later, After Failure of Diet, TPN										
Ijichi, 2008	40, F	PBC	L	Chylous leak in drains	21	Y	Y	N	112	70 d × LF → not effective → 14 d × (NPO + TPN + Oct) → recurrence on resuming diet → 14 d × (NPO + TPN + Oct) → chyle cleared → additional 14 d × (NPO + TPN, no Oct)
Present Case, 2012	62, M	Hep C, HCC	D	Chylous leak from incision and drains	11	Y	Y		70	Surgical closure of partial wound dehiscence and peritoneal washout (no leak found) → 14 d → (FF + OC) → Recurrence on fatty test meal → 6 wk × (FF + OC + TPN on week days and unrestricted diet on weekends) → 14 d × (NPO + OC + Oct) → final resolution.
Conservative Treatment Using Octreotide From the Beginning										
Shapiro, 1996	55, M	Hep C	D	Abdominal distension + chylous leak from incision	10	Y	Y	N	2	8 d × (diuretics + antibiotics: vancomycin, ascitic culture positive for Staphylococcus epidermidis) → 10 d × (NPO + TPN + Oct) → resolution in 2 d of therapy, but continued × 10 d. Clr started on day 7; LF started on day 10; full fat after 1 month. No recurrence.
Baran, 2008	3.5, F	Biliary atresia	L	Abdominal distension	15	Y	Y	N	10	10 d × (NPO + TPN + Oct) → resolution of ascites
Baran, 2008	5, F	Hepato-blastoma	L	Abdominal distension	14	Y	Y	N	14	3 d × (NPO + TPN + Oct) → MCT added to (NPO + TPN + Oct). Total 14 d of treatment. Oct discontinued after 8 d.
Surgical Treatment										
Haberal, 1998	4, F	Byler disease	L	Peritonitis	13	N	N	Y	NA	Laparotomy for suspected peritonitis → leaking lymphatic at root of mesentry in jejunojejunal anastomosis (of Roux-en-Y) found and ligated
Saab, 2006	49, M	Hep C + alcohol + congenital lymphedema tarda	D	Abdominal distension	9 m	Y	N	Y	7 m	Presented with bilateral nonpitting edema and refractory CA after 9 months of OLT. Initially treated with 3 months × (LF + MCT + Orlistat) → failure → peritoneovenous shunt → gradual resolution in next 4 months

Abbreviations: α-1-AT Def, α-1-anti-trypsin deficiency; a, artery; Clr, clear diet; D, deceased donor; ETF, elemental tube feed; FF, fat-free diet; FHF, fulminant hepatic failure; HCC, hepatocellular carcinoma; Hep B, hepatitis B; Hep C, hepatitis C; L, living donor; LF, low-fat diet; MCT, medium chain triglyceride; NM, not mentioned; NPO, non per os; Oct, somatostatin analog, octreotide; PBC, primary biliary cirrhosis; Pre-Tx, pretransplant; Sx, surgery; TPN, total parenteral nutrition; YNS, yellow nail syndrome

Inomata and associates⁴ reported a series of 5 cases of pediatric living-donor liver transplants in which tissue expanders were used to stabilize the graft position. In 1 of their 5 cases, chylous ascites was found, which was treated successfully by fasting and TPN. No further details were offered. Similarly, Wang and associates⁵ mention 1 case of complicating chylous ascites in their series of 7 cases using tissue

expanders and Foley catheter for graft position stabilization in living-donor liver transplants.

Among case reports of chylous ascites after liver transplant, Asfar reports their case after more than 500 performed at their center.⁶ Baran⁷ reports a 1.6% incidence (2/119) in their series of pediatric liver transplants. Ijichi and associates⁸ reported an incidence of 0.66% (1/152).

Cause

Traumatic

Traumatic causes predominate over atraumatic. The most common causes are surgical operations followed by blunt abdominal trauma.⁹

Chylous ascites after OLT is rare with 11 major case reports. Most authors report an incidence $\leq 1\%$. Although rare overall, chylous ascites after oncologic surgeries are more commonly encountered after retroperitoneal lymph node dissection. Chylous ascites is also reported after gastrectomies, nephrectomies, and esophagectomies.^{3,10}

Among nononcologic procedures, it is most commonly seen after aortic operations, accounting for 81% of cases.^{11,12} This is because aortic procedures commonly involve extensive dissection in the major retroperitoneal lymphatics. Other procedures that may result in chylous ascites include operations on the inferior vena cava, portacaval shunt, and donor nephrectomy.^{12,13}

Atraumatic

Only 21% of 614 publications reviewed by Steinmann and associates reported atraumatic causes.¹⁴ In adults, malignancies account for up to 85% of cases of atraumatic chylous ascites.¹⁰ Notable cancers are lymphomas, carcinoid tumors, and Kaposi sarcoma. Cirrhosis and mycobacterial infections are the leading nonmalignant, atraumatic causes.¹⁴ Only 0.5% to 1% of cirrhosis patients may have chylous ascites.^{15,16} In the pediatric population, most atraumatic chylous ascites is due to lymphatic anomalies, usually primary intestinal lymphangiectasias.^{14,17}

Pathophysiological basis of chylous ascites

The pathophysiology of postoperative chylous ascites is poorly understood. Substantial anatomic variability is seen in human lymphatics.¹⁸ Inadvertent operative lymphatic disruption is believed to be the fundamental pathogenetic mechanism. De Hart and associates concluded that a certain degree of lymphatic leak is inevitable after every retroperitoneal dissection, although in most cases, they seal off spontaneously without appreciable clinical consequences.¹⁹ However, every lymphatic injury does not culminate in chylous ascites. In a large animal study, involving over 250 experiments on 74 animals, Blalock and associates suggest the existence of "lymphaticovenous anastomosis." Ligation of both

the major lymphatics and lymphaticovenous anastomoses were necessary to cause chylous collections.²⁰ Although not proven in humans, it is possible that individuals with a paucity of these collaterals may be prone to chylous ascites.¹²

In post-OLT chylous ascites, lymphatic damage at the porta hepatis and retroperitoneum are believed to be responsible.^{6,21} Haberal and associates, during an exploratory laparotomy for undiagnosed acute abdomen after a pediatric OLT, found and ligated a leaking lymphatic at the root of the mesentery near the jejunojunal anastomosis, achieving cure.²¹ Ijichi and associates noted dilated lymphatics around the liver and mesentery during the transplant, which they believed were more liable to surgical damage in their case report of chylous ascites following OLT.⁸ Senyuz and associates blamed disruption of lymphatics near the superior mesenteric vein during construction of a mesentero-portal jump graft to bypass the portal vein thrombosis, or migration of the surgical drain disrupting the cisterna chyli as the cause in their case.²² Although our patient underwent an exploratory laparotomy for partial wound dehiscence and chylous ascites leak, we did not find any lymphatic leakage upon administering methylene-blue in milk per nasogastric tube intraoperatively.

Among nontransplant postoperative causes, chylous ascites was more common after emergency aortic surgery and resection of inflammatory aortic aneurysms.^{11,23} It is also more common after postchemotherapy retroperitoneal lymph node clearance for testicular carcinoma.²⁴ These instances imply more extensive dissection, supporting lymphatic disruption as the cause. Fortunately, only a few patients develop the condition among those that undergo the above mentioned procedures.

Presentation

Interval

Significant variability has been noted in the literature regarding the interval between the causative surgery and presentation. In their collective review, Alami and associates report most cases to present within a "few days to a month after surgery, most commonly after approximately a week." Leibovitch and associates note presentations up to several months after the index operation.²³ Delayed presentation is attributed to adhesions causing extrinsic compression of lymphatics.^{21,22} After abdominal aortic surgeries,

chylous ascites presented in 10 to 24 days (mean, 16.4 days).¹³ Kaas and associates, in a review of chylous ascites after abdominal oncologic surgeries, found most leaks to present within 6 postoperative days.³ Chylous ascites appear to present anywhere from 4 to 21 days after the transplant. In the cases reviewed, it was most commonly seen after about 2 weeks (Table 1). In the present case, the patient presented 11 days postoperatively.

Manifestations

The spectrum of clinical manifestations is variable, but can be categorized as clinically obvious: identification of characteristic fluid in surgical drains or in leakage from the surgical wound; and clinically suspected: abdominal distension, indicating fluid accumulation (chylous ascites being a differential diagnosis, albeit rare), subsequently recognized as chylous by paracentesis; and nonspecific, for example, presenting as acute abdomen then discovered as chylous ascites during exploratory laparotomy. Overall, abdominal distension is the most common presentation.^{10,23}

After a liver transplant, 4 cases presented with chyle in the surgical drains. Two cases, both pediatric, presented with abdominal distension, and 1 case presented mimicking peritonitis. Three cases including ours presented with chylous leakage from a dehiscence portion of the surgical incision and in the drains. One case was diagnosed as a congenital lymphedema tarda aggravated by the chylous ascites that presented as abdominal distension 9 months after the transplant.

Reports of chylous ascites presenting with scrotal edema also are encountered, mostly in children.^{10,25} A prolonged course is accompanied by malnutrition, and metabolic and immunologic consequences.

Laboratory diagnosis

The diagnosis is confirmed by laboratory analysis of the fluid. Chyle is the only body fluid with fat content greater than plasma.¹⁰ The inconsistency in criteria used to define chyle is because of individual variation²⁶ and the effect of diet.²⁷

Generally, an odorless, milky appearing alkaline fluid that separates into layers on standing, having specific gravity > 1.012, showing Sudan Red staining of fat globules, 0.4% to 4% fat content, 3% protein content, and total solids > 4% is considered chylous.²⁸ Triglyceride levels 2 to 8 times plasma levels are

strongly suggestive.²⁹ High leukocyte counts are characteristic of chylous ascites that are predominantly lymphocytes ($\geq 80\%$). Persistent chylous ascites for prolonged durations can therefore cause lymphocytopenia.⁶ Chylomicron demonstration by lipoprotein analysis may help clarify doubtful levels, though such a situation was not seen in cases after liver transplant.¹⁰

In post-OLT cases, triglyceride levels were reported to be between 4.3 mmol/L and 11 mmol/L, and ascitic fluid to serum triglyceride ratios were from 1.9 to 11.2.^{6-8,21,22} In our case, the ascitic fluid triglyceride level was 4.8 mmol/L, plasma level was 1.4 mmol/L, and the ratio was 3.3.

Management of chylous ascites after orthotopic liver transplant

Table 1 summarizes the 11 major case reports of chylous ascites after OLT, classifying them according to treatment approach. Octreotide, dietary measures, TPN, and paracentesis form the pillars of conservative management. These measures are believed to decrease intestinal lymph production and flow, providing an opportunity for the disrupted lymphatics to heal while maintaining nutrition.

Octreotide

Shapiro and associates³⁰ reported the first use of octreotide, a somatostatin analog, for chylous ascites after a liver transplant. Although the mechanism of action is not clearly understood, octreotide is believed to decrease intestinal absorption of fats, lower triglyceride concentrations in the thoracic duct, and attenuate lymph flow in major lymphatic channels.⁷ The dosage used was either 100 μg every 8 hours or 200 μg daily, both subcutaneously.

Of the 11 major case reports of chylous ascites after OLT, 9 were managed successfully without surgery including the present case. In 3 cases, Afsar and associates,⁶ Gaglio and associates,³¹ Senyuz and associates,²² and Koluglu and associates,³² only diet with or without TPN were used; octreotide was not used. Cure was achieved in 3 to 36 days.

In 3 cases, Shapiro and associates,³⁰ and Baran and associates (2 cases),⁷ octreotide was used from the beginning in addition to diet and/or TPN. Cure was achieved within 2 weeks for all these cases.

In 2 cases,⁸ including ours, dietary measures and TPN were used first. After that failed, octreotide was added and cure was achieved in both the cases. After

a failure of dietary measures and TPN for 8 weeks, we used octreotide. We achieved cure within 2 weeks of starting octreotide. Ijichi⁸ used octreotide after a failure of low-fat diet for 70 days. After instituting octreotide, cure was achieved in 4 weeks of treatment. In this case, the delay may have been because of prolonged use of oral low-fat diet instead of fat-free clear diet or nil per os and TPN.

It is to be noted that octreotide used in the setting of post-OLT chylous ascites, never failed, and cure was achieved within 2 weeks of starting the drug in 5 out of 6 cases where it was used. Therefore, we feel that octreotide must be included in the treatment from the beginning and must be used for at least 2 weeks uninterrupted to enable quick control of the condition.³³

Dietary measures

Dietary measures for treating chylous ascites are fat-free clear liquids and elemental feeds. The goal is to reduce thoracic duct flow. Thoracic duct lymph flow when fasting is about 1 mL/h that can rise to 200 to 225 mL/h after a fatty meal.²¹ Medium chain triglycerides (MCT) are absorbed directly from the intestinal lumen into the portal vein, where long chain fatty acids are transported through lymphatics as chylomicrons, thus increasing lymphatic flow.¹⁵ Thus, MCT can provide the dietary fat requirements enterally but extralymphatically. Although MCT may play a physiological role, they may not be consistently effective in practice.^{34,35}

Dietary measures were used in all post-OLT cases of chylous ascites treated conservatively including the present one. Ijichi and associates⁸ reported the use of low-fat diet. This approach was unsuccessful even after 70 days. All other authors used a fat-free diet, including us. Thus, there is a strong argument favoring fat-free over low-fat diet.

Total parenteral nutrition

Total parenteral nutrition provides near complete bowel rest. Goldfarb has reported that even intestinal intraluminal water increases thoracic duct lymph flow.³⁶ In such situations, NPO and TPN can maintain the nutrition of post-OLT patients, while providing near complete bowel and intestinal lymphatic rest. Total parenteral nutrition was used in 7 out of 9 cases managed conservatively with or without octreotide. We also used TPN from the beginning along with other measures.

Paracentesis

Repeated paracentesis can lead to severe nutritional and immunologic depletion.^{13,24} Therefore, it should be reserved for initial diagnosis, periodic assessment of treatment outcome, and relief of mechanical symptoms. In the reported post-OLT cases, paracentesis was used for the above indications. We retained the drain placed during the transplant and used it for draining the ascites at intervals. Retrospectively, we feel that such an approach may not be the best option, considering the risk of infection.

Surgical treatment

Surgery was required to treat post-OLT chylous ascites in 2 of 11 cases. Haberal and associates²¹ undertook exploration as the presentation mimicked peritonitis. The diagnosis of chylous ascites was not known preoperatively, and it was an unexpected finding at surgery. A leaking lymphatic was identified at the porta hepatis and ligated, leading to a cure. Therefore, in this case, conservative management was not used at all.

Saab and associates³⁷ noted a failure of conservative management using low-fat, high-protein diet in conjunction with MCTs and orlistat for 3 months. Then, they performed a peritoneovenous shunt that gradually cured the condition in 4 months. However, in this case, a diagnosis of congenital lymphatic disorder was made by lymphatic studies. Moreover, a trial of strict NPO with TPN and octreotide was not used. In our case, surgery was performed with the intention of closing the partial fascial dehiscence; however, at the time of surgery, no obvious leak was found.

Role of preoperative leak localization

Attempts to intraoperatively visualize lymphatics with fat staining dyes are usually of equivocal use, and staining the entire operative field obscures visibility.²³ In our case, we used whole milk dyed with methylene blue via a nasogastric tube during surgery, but no leak was found.

Although a pathognomonic "fluid-fluid" sign has been reported in CT scan in chylous ascites,³⁸ it has limited clinical use. Lymphangiography is the criterion standard.¹⁰ The procedure may be technically difficult and is fraught with high incidence of local reactions to the oil based dye that is commonly used. Lymphoscintigraphy is used more commonly for its convenience. There are

sporadic reports of success in use of both lymphangiography^{39,40} and lymphoscintigraphy⁴¹ before surgery, but they are inconsistent. Pui and associates⁴² concluded that lymphoscintigraphy could demonstrate abnormal lymphatics in chylous complications and should be considered in selecting patients for surgery.

Only Saab and associates³⁷ used lymphatic imaging in post-OLT cases. They discovered congenital lymphedema tarda. We feel that preoperative imaging localization of a lymphatic leak may aid in selecting patients for surgery, especially when candidates are of questionable surgical risk.^{10,23}

Chylous ascites after OLT is exceptionally uncommon (11 major case reports). If exploration is undertaken for any other indication in post-OLT chylous ascites, then identifying a leak and ligating it is the best treatment. If there is to be no surgical intervention, octreotide should be used from the beginning, as it has been reported not to fail in post-OLT chylous ascites. Dietary modifications like oral fat-free clear diet supplemented with MCT or NPO with TPN are adjunct measures to octreotide.

References

- Almakdisi T, Massoud S, Makdisi G. Lymphomas and chylous ascites: review of the literature. *Oncologist*. 2005;10(8):632-635.
- Vasko JS, Tapper RI. The surgical significance of chylous ascites. *Arch Surg*. 1967;95(3):355-368.
- Kaas R, Rustman LD, Zoetmulder FA. Chylous ascites after oncological abdominal surgery: incidence and treatment. *Eur J Surg Oncol*. 2001;27(2):187-189.
- Inomata Y, Tanaka K, Egawa H, et al. Application of a tissue expander for stabilizing graft position in living-related liver transplantation. *Clin Transplant*. 1997;11(1):56-59.
- Wang CC, Concejero AM, Yong CC, et al. Improving hepatic and portal venous flows using tissue expander and Foley catheter in liver transplantation. *Clin Transplant*. 2006;20(1):81-84.
- Asfar S, Lowndes R, Wall WJ. Chylous ascites after liver transplantation. *Transplantation*. 1994;58(3):368-369.
- Baran M, Cakir M, Yükksekaya HA, et al. Chylous ascites after living related liver transplantation treated with somatostatin analog and parenteral nutrition. *Transplant Proc*. 2008;40(1):320-321.
- Ijichi H, Soejima Y, Taketomi A, et al. Successful management of chylous ascites after living donor liver transplantation with somatostatin. *Liver Int*. 2008;28(1):143-145.
- Haan JM, Montgomery S, Novosel TJ, Stein DM, Scalea TM. Chyloperitoneum after blunt abdominal injury. *Am Surg*. 2007;73(8):811-813.
- Aalami OO, Allen DB, Organ CH Jr. Chylous ascites: a collective review. *Surgery*. 2000;128(5):761-778.
- Combe J, Buniet JM, Douge C, Bernard Y, Camelot G. Chylothorax and chylous ascites following surgery of an inflammatory aortic aneurysm. Case report with review of the literature [in French]. *J Mal Vasc*. 1992;17(2):151-156.
- Ohri SK, Patel T, Desa LA, Spencer J. The management of postoperative chylous ascites. A case report and literature review. *J Clin Gastroenterol*. 1990;12(6):693-697.
- Pabst TS 3rd, McIntyre KE Jr, Schilling JD, Hunter GC, Bernhard VM. Management of chyloperitoneum after abdominal aortic surgery. *Am J Surg*. 1993;166(2):194-198; discussion 198-199.
- Steinemann DC, Dindo D, Clavien PA, Nocito A. Atraumatic chylous ascites: systematic review on symptoms and causes. *J Am Coll Surg*. 2011;212(5):899-905.e1-e4. doi: 10.1016/j.jamcollsurg.2011.01.010
- Ablan CJ, Littooy FN, Freeark RJ. Postoperative chylous ascites: diagnosis and treatment. A series report and literature review. *Arch Surg*. 1990;125(2):270-273.
- Arora M, Dubin E. A clinical case study: sclerosing mesenteritis presenting as chylous ascites. *Medscape J Med*. 2008;10(2):30.
- Meltzer E, Goshen E, Fridman E, Sidi Y. Diffuse lymphangiomatosis - a fatal case with atypical skeletal features. *Am J Med Sci*. 2008;336(5):445-448.
- van Pernis PA. Variations of the thoracic duct. *Surgery*. 1949;26(5):806-809.
- DeHart MM, Lauerman WC, Conely AH, Roettger RH, West JL, Cain JE. Management of retroperitoneal chylous leakage. *Spine (Phila Pa 1976)*. 1994;19(6):716-718.
- Blalock A, Robinson CS, Cunningham RS, Gray ME. Experimental studies on lymphatic blockage. *Arch Surg*. 1937;34(6):1049-1071.
- Haberal M, Karakayali H, Moray G, Bilgin N. Surgical treatment of chylous ascites following partial living-related liver transplantation. *Transpl Int*. 1998;11(4):327-328.
- Senyüz OF, Sentürk H, Taşçı H, Kaya G, Ozbay G, Sariyar M. Chylous ascites after liver transplantation with mesentero-portal jump graft. *J Hepatobiliary Pancreat Surg*. 2001;8(6):571-572.
- Leibovitch I, Mor Y, Golomb J, Ramon J. The diagnosis and management of postoperative chylous ascites. *J Urol*. 2002;167(2 Pt 1):449-457.
- Baniel J, Foster RS, Rowland RG, Bihle R, Donohue JP. Management of chylous ascites after retroperitoneal lymph node dissection for testicular cancer. *J Urol*. 1993;150(5 Pt 1):1422-1424.
- Link RE, Amin N, Kavoussi LR. Chylous ascites following retroperitoneal lymphadenectomy for testes cancer. *Nat Clin Pract Urol*. 2006;3(4):226-232; quiz 233.
- Roy JB, Abdulian M, Walton KN. Chylous ascites. *J Urol*. 1970;103(3):343-344.
- Varekamp AP, Spruit M, Bosman CH. Chylous ascites after aortic replacement. *Eur J Surg*. 1992;158(11-12):623-625.
- Jahsman W. Chylothorax. Brief review of literature: Report of 3 nontraumatic cases. *Ann Intern Med*. 1944;21:669-678.
- Ward PC. Interpretation of ascitic fluid data. *Postgrad Med*. 1982;71(2):171-173, 176-178.
- Shapiro AM, Bain VG, Sigalet DL, Kneteman NM. Rapid resolution of chylous ascites after liver transplantation using somatostatin analog and total parenteral nutrition. *Transplantation*. 1996;61(9):1410-1411.
- Gaglio PJ, Leevy CB, Koneru B. Peri-operative chylous ascites. *J Med*. 1996;27(5-6):369-376.
- Kuloğlu Z, Ustündağ G, Kırşacıoğlu CT, et al. Successful living-related liver transplantation in a child with familial yellow nail syndrome and fulminant hepatic failure: report of a case. *Pediatr Transplant*. 2008;12(8):906-909.
- Yılmaz M, Akbulut S, Isik B, et al. Chylous ascites after liver transplantation: incidence and risk factors. *Liver Transpl*. 2012;18(9):1046-1052. doi: 10.1002/lt.23476.
- Man DW, Spitz L. The management of chylous ascites in children. *J Pediatr Surg*. 1985;20(1):72-75.
- Unger SW, Chandler JG. Chylous ascites in infants and children. *Surgery*. 1983;93(3):455-461.
- Goldfarb JP. Chylous effusions secondary to pancreatitis: case report and review of the literature. *Am J Gastroenterol*. 1984;79(2):133-135.
- Saab S, Nguyen S, Collins J, Kunder G, Busuttill RW. Lymphedema tarda after liver transplantation: a case report and review of the literature. *Exp Clin Transplant*. 2006;4(2):567-570.
- Hibbeln JF, Wehmueller MD, Wilbur AC. Chylous ascites: CT and ultrasound appearance. *Abdom Imaging*. 1995;20(2):138-140.
- Cope C. Diagnosis and treatment of postoperative chyle leakage via percutaneous transabdominal catheterization of the cisterna chyli: a preliminary study. *J Vasc Interv Radiol*. 1998;9(5):727-734.

40. Kohnoe S, Takahashi I, Kawanaka H, Mori M, Okadome K, Sugimachi K. Combination of preoperative lymphangiography using lipiodol and intraoperative lymphangiography using Evans Blue facilitates the accurate identification of postoperative chylous fistulas. *Surg Today*. 1993;23(10):929-931.
41. Andrews JT, Binder LJ. Lymphoscintigraphy pre- and post-surgical lymphatic leak repair. *Australas Radiol*. 1996;40(1):19-21.
42. Pui MH, Yueh TC. Lymphoscintigraphy in chyluria, chyloperitoneum and chylothorax. *J Nucl Med*. 1998;39(7):1292-1296.